HAL
open science

Turbellarian black spot disease in bluespine unicornfish Naso unicornis in New Caledonia, caused by the parasitic turbellarian Piscinquilinus sp.

Jean-Lou Justine, P. Leblanc, F. Keller, R. J. G. Lester

To cite this version:

Jean-Lou Justine, P. Leblanc, F. Keller, R. J. G. Lester. Turbellarian black spot disease in bluespine unicornfish Naso unicornis in New Caledonia, caused by the parasitic turbellarian Piscinquilinus sp.. Diseases of Aquatic Organisms, 2009, 85 (3), pp.245-249. 10.3354/dao02082 . ird-00422976

HAL Id: ird-00422976

https://ird.hal.science/ird-00422976v1

Submitted on 9 Oct 2009

HAL is a multi-disciplinary open access archive for the deposit and dissemination of scientific research documents, whether they are published or not. The documents may come from teaching and research institutions in France or abroad, or from public or private research centers.

L'archive ouverte pluridisciplinaire **HAL**, est destinée au dépôt et à la diffusion de documents scientifiques de niveau recherche, publiés ou non, émanant des établissements d'enseignement et de recherche français ou étrangers, des laboratoires publics ou privés.

Manuscript published in Diseases of Aquatic Organisms 85: 245-249, 2009
doi: 10.3354/dao02082

Turbellarian black spot disease in bluespine unicornfish, *Naso unicornis*, in New Caledonia, due to the parasitic turbellarian *Piscinquilinus* sp.

Jean-Lou Justine [1]*, Philippe Leblanc [2], Florent Keller [2] & Robert J.G. Lester [3]

[1] Équipe Biogéographie Marine Tropicale, Unité Systématique, Adaptation, Évolution (CNRS, UPMC, MNHN, IRD), Institut de Recherche pour le Développement, BP A5, 98848 Nouméa Cedex, Nouvelle-Calédonie
[2] Aquarium des Lagons, BP 8185, 98807 Nouméa, Nouvelle-Calédonie.
[3] Parasitology, SCBS, The University of Queensland, Brisbane, Qld 4072, Australia
* Author for correspondence, e-mail: justine@ird.nc

ABSTRACT: Turbellarian black spot disease is described in a bluespine unicornfish, *Naso unicornis* (Perciformes, Acanthuridae), collected from the wild off Nouméa, New Caledonia, South Pacific. Each cyst contained a whitish worm, 2-4 mm in length, which was able to swim freely in seawater. Cyst walls consisted of fibrous tissue with a scattering of melanocytes. Worms had two eyespots at the anterior end, a pharynx at the posterior end and a largely undeveloped reproductive system. They were identified as *Piscinquilinus* sp. (= *Ichthyophaga* sp.), a genostomatid turbellarian. The disease spread within two weeks from a single infected fish to three other unicornfish in the same tank, in spite of copper sulphate and diluted seawater treatment; however, other fish from several families kept in the same tank were not infected, suggesting specificity of these parasites. Praziquantel injections into the infected fish eliminated the infection. Other cases of turbellarian infections are reported from 7 fish species off New Caledonia; prevalence is very low (0.3%).

KEY WORDS: Black Spot Disease, Fish, *Naso unicornis*, Turbellaria, New Caledonia, *Piscinquilinus*, *Ichthyophaga*

INTRODUCTION

The 'Turbellaria' generally differ from the parasitic flatworms (or Neodermata) by their free-living (non parasitic) life. However, a few species are parasitic and parasitise marine invertebrates such as molluscs and some fish species (Cannon 1986). In tropical fish, species from two genera, *Paravortex* and *Piscinquilinus*, are known to produce 'black spot disease' (Cannon & Lester 1988).

The unicorn tang or bluespine unicornfish, *Naso unicornis*, is abundant in the lagoon of New Caledonia. It is very common at fish markets where it is sold under the local name of 'dawa', is particularly prized as food, and has a good reputation of being devoid of ciguatera-poisoning. The black-spot disease described here concerned aquarium fish, but there is no doubt that the appearance of the infected animal would have a negative impact on sales, since unicornfish are sold whole.

In this paper, we describe the external aspect of turbellarian black spot disease in wild specimens of unicornfish caught for aquarium purposes, report the treatment used to try to cure the disease, and explain how the parasite could be identified. In addition, records of similar turbellarian parasites found in wild fish from New Caledonia are reported.

MATERIAL AND METHODS

Fish were caught by divers at night with nets at Récif Larégnère off Nouméa, New Caledonia (22 April 2008, 22°19'50"S, 166°18'35"E), for inclusion in the aquarium. In addition to four bluespine unicornfish, *Naso unicornis* (Acanthuridae; Fork Length 400-500 mm), other species included 2 *Heniochus chrysostomus* (Chaetodontidae), 1 *Heniochus varius*, 1 *Chaetodon auriga* (Chaetodontidae), 1 *Parupeneus indicus* (Mullidae), 1 *Parupeneus multifasciatus*, 1 *Gymnothorax* sp. (Muraenidae), 1 *Scarus* sp. (Scaridae), 1 *Forcipiger flavissimus* (Chaetodontidae), 1 *Caesio caerulaurea* (Caesionidae). All fish were transferred in a 2,500 l tank for examination and quarantine before being included in the display tank. Black spots were noticed on one fish and a treatment was applied (see results).

Tissue containing two black cysts was excised and fixed in Bouin's fixative. It was later embedded in wax, sectioned at 5 um and stained with haematoxylin-eosin. Whole worms and histological sections are deposited in the MNNH, Paris, ref JNC2556 and the Queensland Museum, Brisbane, cat nos G 231341-231344.

RESULTS

Progression of the disease and treatment

On day 1 (23 April 2008) black spots were noticed on one unicornfish (out of 4). Other fish were not infected.

From day 1 to day 7, all fish, including the 4 unicornfish, were routinely kept in a closed-circuit 2,500 litres tank with 15mg/l Copper Sulphate and diluted seawater (density 1020) at a temperature of 28°C. This is the routine quarantine method used in the Nouméa aquarium.

On day 7, black spots were noticed on a second unicornfish. All other fish species appeared healthy and were separated from the unicornfish for further inclusion in the display tanks.

From day 7 to day 17, the 4 unicornfish were kept in the same closed-circuit tank with copper sulphate and diluted seawater.

On day 17, the 4 unicorn fish were transferred to an open circuit tank in plain seawater. They were injected with Praziquantel (Droncit, 0.2–0.4ml per fish, i.e. 17 mg Praziquantel per fish).

On day 26, all 4 unicorn fish displayed black spots. One individual was collected for further parasitological study.

On day 32, the 3 remaining unicorn fish were again injected with Praziquantel (17 mg/fish).

From day 32 to day 60, black spots diminished progressively and eventually vanished. The 3 unicornfishes were finally released.

Parasitological examination of one fish

The unicorn fish collected on day 26 was photographed on both sides (Fig. 1A, B). About 20 black spots were counted. The black spots appeared as swellings, 2-4 mm in diameter, and no opening was visible. No parasite was visible from the outside (Fig. 1C). When gently opened with the fine point of a Dumont pincer and delicately pressed, each black spot produced a single worm, 2-4mm in length (Fig. 1D). The worms were whitish or yellowish, probably showing different states of maturation; they were able to swim actively in sea water, and eyes were visible at the anterior end.

Further microscopic examination of living parasites in seawater between a slide and a cover slip failed because the worms were sensitive to pressure and exploded leaving no identifiable elements.

Microscopic examination of preserved parasites

Preserved cysts contained a single worm. In histological sections, eyes were distinguished at one end of the worm (Fig. 1E) and a pharynx at the other (Fig. 1F), ascertaining that the parasites belongs to the genus *Piscinquilinus* (Platyhelminthes, Prolecithophora, Genostomatidae Von Graff, 1903). The centre of the worm contained cells resembling host leucocytes. Around this mass were numerous multinucleate cells possibly associated with intracellular digestion. Outside of this was a layer of refractile non-staining granular cells interspersed with occasional large eosinophilic cells. The rhabdite/ciliary layers appeared fused and formed a dense basophilic layer around the worms. In one specimen, a small area of glandular tissue and what appeared to be spermatogonia occurred in the granular layer.

The cyst wall consisted of a thick layer of fibrous tissue within which were capillaries and scattered melanocytes (Fig. 1E). At the end of one cyst opposite the pharynx was a developing granuloma with leucocytes and erythrocytes similar to the cell mass in the gut of the worm. In the second specimen at one end of the cyst and near the surface of the fish was a large area of dying cells (Fig. 1G). This was adjacent to an area of fluid accumulation within the cyst. Some host cell debris was inside the cyst wall at this point suggesting that cyst wall had been perforated.

Records of similar turbellarians in other wild fish

In New Caledonia, more than 2500 wild coral reef fish belonging to 270 species were examined by one of us (JLJ) on a 6-year period (2003-2008). Only 7 cases of turbellarian parasite infections were noticed (Table 1), each time with a single case in 7 species of fish. General prevalence was 0.3% (7/2500). Parasites reported in Table 1 were not processed for microscopy and it was not determined if they belonged to *Paravortex* or *Piscinquilinus*.

Among 18 specimens of *Naso unicornis* taken from the wild (2003-2008) and examined by JLJ, none was infected. Among the hundreds of fish examined at the Nouméa aquarium, black spot disease was not noticed before the unicorn fish mentioned in this study.

DISCUSSION

Black spot diseases in fish have been attributed to metacercariae (Moller & Anders 1986, Shukhgalter & Chukalova 2002, Ondrackova et al. 2004, Quist et al. 2007) and turbellarians (Cannon & Lester 1988). Turbellaria can be distinguished from metacercariae after releasing them from the cyst by their mechanism of movement. Turbellaria have cilia on the surface on which they glide whereas metacercariae are devoid of cilia and generally move by peristalsis. Of the turbellarians from fish, *Paravortex* species have eyes and pharynx in the anterior of the body, whereas *Piscinquilinus* have anterior eyes and a posterior pharynx (Cannon & Lester 1988).

The closely related turbellarians, *Piscinquilinus* and *Urastoma* are symbiotic worms, *Urastoma* being found in molluscs, and *Piscinquilinus* in fish (Cannon, 1986). *Urastoma* species possess a muscular penis bulb, a feature absent from *Piscinquilinus* and from our specimens.

The genus *Piscinquilinus* currently contains the single species, *Piscinquilinus subcutaneus* (Syromiatnikova, 1949) Sluys & Kawakatsu, 2005. *Piscinquilinus* Sluys & Kawakatsu, 2005 is a replacement name for *Ichthyophaga* Syromiatnikova, 1949, preoccupied by a bird. *Piscinquilinus* (as *Ichthyophaga*) was classified within the Prolecithophora by Cannon (1986) but molecular analyses by Lockyer et al. (2003) suggest a phylogenetic position within a sister-group to the Neodermata (the 'true' parasitic Platyhelminthes). Further molecular analyses are needed to distinguish species of *Piscinquilinus*, not least on account of the poorly defined reproductive structures of what appear to be essentially immature worms when they are in fish.

Piscinquilinus subcutaneus was described from within the skin and fins of two benthic temperate water fishes, the cottid *Bero elegans* and the greenling *Hexagrammos decagrammus*, both taken in the Ussurian Gulf east of Vladivostok (latitude 44°N) (Syromiatnikova, 1949). Later, Menitskii (1963) gave a detailed description of what he thought was the same worm, though much smaller (0.35–0.5 mm v. up to 4.4 mm), from the gills of the tropical serranid *Cephalopholis pachycentron* (a junior synonym of *C. boenak*) (locality unstated). Our worms were of a similar size to that reported in the original description but were whitish rather than brick red and taken in the tropics (latitude 22°S).

There are no previous records of Turbellaria from New Caledonia (Justine 2007). Thus, all turbellarian infections reported in Table 1 are new records for New Caledonia, as is the *Naso unicornis* infection. Infections with parasitic turbellarians seem to be rare in coral

fish taken from the wild: our results in New Caledonia show that their prevalence was less than 0.3%. On the Great Barrier Reef turbellarians were rarely seen at Heron Island in the south but were occasionally found at Lizard Island in the north (Grutter 1994). Those found were pale and less than 1.3 mm long (Cannon & Lester 1988, Grutter 1994) suggesting that they were different species from *P. subcutaneus* or the one we found in New Caledonia.

Parasitic turbellarians of fish such as *Paravortex* and *Piscinquilinus* spp. are believed to have a single host life-cycle. *Paravortex* spp. are viviparous and produce many juveniles (Cannon & Lester 1988), the life cycle of one species being completed within 10 days (Kent & Olson 1986). This ensures rapid spreading of the disease within a confined volume of sea water. *Piscinquilinus* spp. may not be viviparous and may have a longer life cycle. Our specimens remained on the fish for at least 30 days. The cyst wall laid down by the fish became a thick organised layer of fibrous tissue and capillaries, very different from the temporary epidermal pockets described for *Paravortex* spp. (Kent 1981, Cannon & Lester 1988). The lack of well developed reproductive organs in the worm suggests maturation only occurs after the worm has left the fish. This is consistent with the apparent break in the cyst wall shown in Fig. 1G and the observation that of five melanised cysts dissected by Cannon and Lester (1988) only three contained a turbellarian, the others were empty. Once away from the fish the worms presumably produce a cocoon within which they reproduce, as has been described for the closely related *Urastoma cyprinae* by Gonzalez et al. (2005).

Though some turbellarian species such as *Paravortex* sp. infest a wide variety of fishes (Kent & Olson 1986), *Piscinquilinus* species may be more host specific. Our infected unicornfish was kept in a tank with several species of fish and the disease was apparently transmitted only to fish of the same species, although fish belonging to families such as scarids are known to be sensitive to *Piscinquilinus* infections (Cannon & Lester 1988). This apparent specificity suggests that several cryptic *Piscinquilinus* species, each relatively specific, could be present in natural conditions, rather than a single generalist species.

Turbellarian diseases have implications for the health of ornamental fishes and the quality of aquarium displays because the black spots are aesthetically unappealing and can be easily noticed by the public. It has also, of course, negative implications for the health of cultured fish and their economic value.

A 17-day treatment with copper and diluted seawater did not cure the infected fish and apparently did not stop the infection being transmitted to other fish. The treatment with Praziquantel was associated with the decline of the infection only after two injections. Praziquantel has already been demonstrated to be effective against monogenean parasites (e.g.

Schmahl & Mehlhorn 1985, Williams et al. 2007, Fajer-Avila et al. 2007) and it is logical that it was effective against another platyhelminth worm; however, the cyst wall might slow down transmission of the drug to the parasite, explaining why two injections were necessary to stop the infection.

Acknowledgements. The fish were collected under a permit from Province Sud, New Caledonia. C. Dupoux, IRD, helped in the parasitological investigation and C. Cazier, UQ, prepared the histological sections.

Table 1. Turbellarian parasites found in coral reef fish off Nouméa, New Caledonia. These are the only few reports among more than 2,500 fish examined from 2003 to 2008.

Family	**Fish species**	**Organ**	**Date found**	**Prevalence**
Acanthuridae	*Acanthurus xanthopterus*	skin	May 2003	1/4
Chaetodontidae	*Chaetodon ephippium*	skin	May 2003	1/2
Labridae	*Cheilinus chlorourus*	gills	March 2003	1/6
Labridae	*Thalassoma lutescens*	skin, fins, gills	February 2003	1/7
Nemipteridae	*Nemipterus furcosus*	gills	November 2007	1/200
Pomacentridae	*Chromis viridis*	fins	May 2006	1/9
Serranidae	*Epinephelus fasciatus*	skin	June 2003	1/100

LITERATURE CITED

Cannon LRG (1986) Turbellaria of the world. Queensland Museum, Brisbane

Cannon LRG, Lester RJG (1988) Two turbellarians parasitic in fish. Dis Aquat Org 5:15–22

Fajer-Avila EJ, Velasquez-Medina SP, Betancourt-Lozano M (2007) Effectiveness of treatments against eggs, and adults of *Haliotrema* sp and *Euryhaliotrema* sp (Monogenea: Ancyrocephalinae) infecting red snapper, *Lutjanus guttatus*. Aquaculture 264:66–72

Gonzalez CC, Alvarez RMR, Dominguez HR, Bua MS, Iglesias R, Fernandez CA, Esteves JMC (2005) In vitro reproduction of the turbellarian *Urastoma cyprinae* isolated from *Mytilus galloprovincialis*. Mar Biol 147:755–760

Grutter AS (1994) Spatial and temporal variations of the ectoparasites of seven reef fish species from Lizard Island and Heron Island, Australia. Mar Ecol Progr Ser 115:21–30

Justine J-L (2007) Fish parasites: Platyhelminthes (Monogenea, Digenea, Cestoda) and Nematodes, reported from off New Caledonia. In: Payri CE & Richer de Forges B (eds.), Compendium of marine species from New Caledonia. Documents Scientifiques et Techniques II7, Deuxième Edition, pp. 183–198, Institut de Recherche pour le Développement, Nouméa, New Caledonia

Kent ML (1981) The life cycle and treatment of a turbellarian disease of marine fishes. Freshw Mar Aqu Mag 4:11–13

Kent ML, Olson AC (1986) Interrelationships of a parasitic turbellarian (*Paravortex* sp.) (Graffillidae, Rhabdocoela) and its marine fish hosts. Fish Pathol 21:65–72

Lockyer AE, Olson PD, Littlewood DTJ (2003) Utility of complete large and small subunit rRNA genes in resolving the phylogeny of the Neodermata (Platyhelminthes): implications and a review of the cercomer theory. Biol J Linn Soc 78:155–171

Menitskii YL (1963) Structure and systematic position of the turbellarian *Ichthyophaga subcutanea* Syromjatnikova 1949, parasitising fish. Parazit Sb 21:245–258 (in Russian)

Moller H, Anders K (1986) Diseases and parasites of marine fishes. Verlag Moller, Kiel

Ondrackova M, Bartosova S, Valova Z, Jurajda P, Gelnar M (2004) Occurrence of black-spot disease caused by metacercariae of *Posthodiplostomum cuticola* among juvenile fishes in water bodies in the Morava River basin. Acta Parasitol 49:222–227

Quist MC, Bower MR, Hubert WA (2007) Infection by a black spot-causing species of *Uvulifer* and associated opercular alterations in fishes from a high-desert stream in Wyoming. Dis Aquat Org 78:129–136

Schmahl G, Mehlhorn H (1985) Treatment of fish parasites.1. Praziquantel effective against Monogenea (*Dactylogyrus vastator*, *Dactylogyrus extensus*, *Diplozoon paradoxum*). Z Parasitenkde-Parasitol Res 71:727–737

Shukhgalter O, Chukalova N (2002) An investigation of "black spot" disease of bream (*Abramis brama*) from the Curonian Lagoon, south-eastern Baltic Sea. Bull Eur Ass Fish Pathol 22:218–221

Sluys R, Kawakatsu M (2005) A replacement name for *Ichthyophaga* Syromiatnikova, 1949 (Platyhelminthes: Prolecithophora), with a nomenclatural analysis of its avian senior homonym. Species Divers 10:63–68

Syromiatnikova IP (1949) A new turbellarian parasitic in fish and called *Ichthyophaga subcutanea*. Dokl Akad Nauk SSSR 68: 805–808 (in Russian)

Williams RE, Ernst I, Chambers CB, Whittington ID (2007) Efficacy of orally administered praziquantel against *Zeuxapta seriola*e and *Benedenia seriolae* (Monogenea) in yellowtail kingfish *Seriola lalandi*. Dis Aquat Org 77:199–205

FIGURE LEGENDS

Fig. 1. A, B. Bluespine unicornfish, *Naso unicornis*, infected with black spot disease. Photographs of both sides of the dead fish; the discoloured area in the centre of the fish in B is an artefact due to wet skin. C. Black spot on the skin. D. Live turbellarian, *Piscinquilinus* sp., extracted from a cyst and swimming in sea water. E–G. *Piscinquilinus* sp. in skin of *Naso unicornis*, haematoxylin-eosin section. E. Arrow, eye-spot; m melanophore. F. Arrow, pharynx; d developing granuloma with free erythrocytes and leucocytes. G. Margin of cyst showing region of dying host cells (arrow). Scale bars in C, D are approximate.

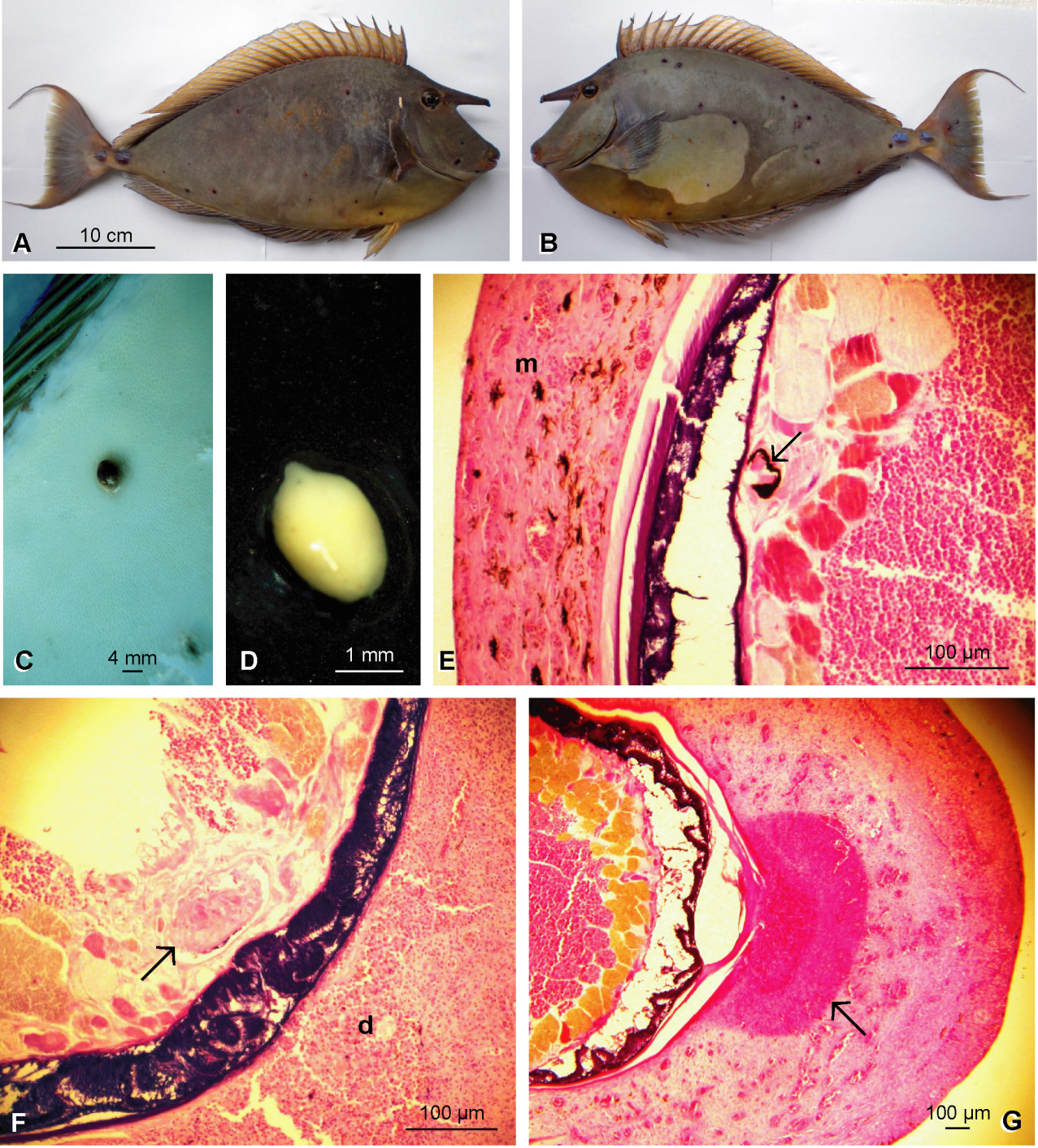
A
10 cm
B
C
4 mm
D
1 mm
E
m
100 µm
F
d
100 µm
G
100 µm